

Ranibizumab versus Verteporfin Photodynamic Therapy for Neovascular Age-Related Macular Degeneration: Two-Year Results of the ANCHOR Study

David M. Brown, MD,¹ Mark Michels, MD,² Peter K. Kaiser, MD,³ Jeffrey S. Heier, MD,⁴ Judy P. Sy, PhD,⁵
Tsoncho Ianchulev, MD, MPH⁵

Objective: The 2-year, phase III trial designated *Anti-vascular endothelial growth factor (VEGF) Antibody for the Treatment of Predominantly Classic Choroidal Neovascularization (CNV) in Age-related Macular Degeneration (ANCHOR)* compared ranibizumab with verteporfin photodynamic therapy (PDT) in treating predominantly classic CNV.

Design: Multicenter, international, randomized, double-masked, active-treatment-controlled clinical trial.

Participants: Patients with predominantly classic, subfoveal CNV not previously treated with PDT or antiangiogenic drugs.

Intervention: Patients were randomized 1:1:1 to verteporfin PDT plus monthly sham intraocular injection or to sham verteporfin PDT plus monthly intravitreal ranibizumab (0.3 mg or 0.5 mg) injection. The need for PDT (active or sham) retreatment was evaluated every 3 months using fluorescein angiography (FA).

Main Outcome Measures: The primary, intent-to-treat efficacy analysis was at 12 months, with continued measurements to month 24. Key measures included the percentage losing <15 letters from baseline visual acuity (VA) score (month 12 primary efficacy outcome measure), percentage gaining ≥ 15 letters from baseline, and mean change over time in VA score and FA-assessed lesion characteristics. Adverse events were monitored.

Results: Of 423 patients (143 PDT, 140 each in the 2 ranibizumab groups), the majority ($\geq 77\%$ in each group) completed the 2-year study. Consistent with results at month 12, at month 24 the VA benefit from ranibizumab was statistically significant ($P < 0.0001$ vs. PDT) and clinically meaningful: 89.9% to 90.0% of ranibizumab-treated patients had lost <15 letters from baseline (vs. 65.7% of PDT patients); 34% to 41.0% had gained ≥ 15 letters (vs. 6.3% of PDT group); and, on average, VA was improved from baseline by 8.1 to 10.7 letters (vs. a mean decline of 9.8 letters in PDT group). Changes in lesion anatomic characteristics on FA also favored ranibizumab (all comparisons $P < 0.0001$ vs. PDT). Overall, there was no imbalance among groups in rates of serious ocular and nonocular adverse events. In the pooled ranibizumab groups, 3 of 277 (1.1%) patients developed presumed endophthalmitis in the study eye (rate per injection = 3/5921 [0.05%]).

Conclusions: In this 2-year study, ranibizumab provided greater clinical benefit than verteporfin PDT in patients with age-related macular degeneration with new-onset, predominantly classic CNV. Rates of serious adverse events were low.

Financial Disclosure(s): Proprietary or commercial disclosure may be found after the references. *Ophthalmology* 2009;116:57–65 © 2009 by the American Academy of Ophthalmology.



Neovascular age-related macular degeneration (AMD) is the process of anomalous pathologic blood vessels arising from the choroid and disrupting the anatomy and function of the neurosensory retina. Choroidal neovascularization (CNV) can be classified on the basis of its appearance on fluorescein angiography (FA) as “occult” or “classic.” The clinical course of vision loss associated with occult CNV, which is usually confined to the space beneath the retinal pigment epithelium (RPE), is typically indolent compared with “classic” CNV lesions, which often penetrate the RPE and grow in the subretinal space.^{1–3} “Predominantly clas-

sic” CNV are lesions composed of at least 50% classic CNV. Before the approval of verteporfin (Visudyne; Novartis Pharmaceuticals Corp., East Hanover, NJ) in 2001, predominantly classic CNV typically led to permanent loss of the majority of central vision within 3 to 9 months after diagnosis.⁴ The Treatment of Age-Related Macular Degeneration with Photodynamic Therapy (TAP) study demonstrated the efficacy and favorable adverse events profile of verteporfin photodynamic therapy (PDT) in patients with predominantly classic CNV over the natural history of the disease, with 59% of patients treated with PDT losing fewer

than 15 letters at 2 years (compared with 31% of patients treated with placebo).⁵ On the basis of these findings, PDT became the standard of care for patients with this angiographic subtype of CNV.

The 2-year, phase III trial designated *Anti-vascular endothelial growth factor (VEGF) Antibody for the Treatment of Predominantly Classic Choroidal Neovascularization in Age-related Macular Degeneration (ANCHOR)* compared the recombinant, humanized anti-VEGF monoclonal antibody antigen-binding fragment (Fab) ranibizumab (Lucentis; Genentech, Inc., South San Francisco, CA) with PDT in patients with predominantly classic, subfoveal CNV secondary to AMD. At 12 months (the prespecified primary efficacy analysis), ranibizumab had superior efficacy to PDT as indicated by both visual acuity (VA) measures and changes in CNV lesion characteristics.⁶ The percentage of patients who had lost fewer than 15 letters from baseline VA (primary efficacy end point) was 94.3% and 96.4% in the 0.3-mg and 0.5-mg ranibizumab groups, respectively, compared with 64.3% of patients in the PDT group. Also, ranibizumab-treated patients, on average, had improved VA compared with baseline at month 12, whereas VA declined in the PDT group. This was the first demonstration that a therapy could not only prevent further VA loss but also provide clinically meaningful improvement of VA in a substantial proportion of patients with predominantly classic CNV. Serious ocular events associated with treatment were uncommon. These first-year results, together with positive 2-year results in a similarly designed, sham-injection-controlled phase III trial in patients with minimally classic or occult with no classic CNV lesions (the *Minimally Classic/Occlude Trial of the Anti-VEGF Antibody Ranibizumab in the Treatment of Neovascular Age-Related Macular Degeneration (MARINA) study*⁷), led to United States Food and Drug Administration approval of ranibizumab for treatment of all angiographic subtypes of CNV secondary to AMD in June 2006. The ANCHOR study is completed, and the 2-year results are reported here.

Materials and Methods

The methods for the ANCHOR study have been reported⁶ and are summarized briefly below.

ANCHOR was a multicenter (83 sites), international, randomized, double-masked, active-treatment-controlled phase III trial evaluating the efficacy and adverse events profile of ranibizumab in treating predominantly classic subfoveal CNV secondary to AMD that, on the basis of FA and fundus photography, was confirmed by an independent central reading center (the University of Wisconsin Fundus Photograph Reading Center) to be predominantly classic in composition and suitable for treatment with PDT. Predominantly classic lesions were defined as those where the classic component made up 50% or more of the total lesion area, which could include, in addition to CNV, components such as contiguous subretinal hemorrhage, blocked fluorescence not from hemorrhage, serous detachment of the RPE, and fibrosis.

Patients provided written, informed consent for study participation. Institutional Review Board, National Competent Authority, or Ethics Committee approval was obtained at each participating clinical center before the start of the study. All US study sites complied with the Health Insurance Portability and Accountability

Act of 1996. Patients were excluded if they had permanent structural damage to the central fovea or a history of treatment for subfoveal neovascular AMD (including any prior PDT) that by its nature or timing might compromise valid assessment of the effects of the study treatment. There were no exclusion criteria regarding preexisting cardiovascular, cerebrovascular, or peripheral vascular conditions.

Only 1 eye per patient (the study eye) received the study treatment. Eligible patients were randomized 1:1:1 to either verteporfin PDT plus monthly sham ocular injection or sham verteporfin PDT plus monthly intravitreal ranibizumab (0.3 mg or 0.5 mg) injection. Ranibizumab was injected into the study eye every 30 ± 7 days for a total of 24 injections beginning on day 0; sham injections were administered on the same dosing schedule. Patients' CNV lesions were evaluated using FA at screening and then every 3 months to assess the need for additional PDT (active or sham intravenous verteporfin injection). The central reading center assessed all images, but the decision to retreat with PDT (active or sham) was based on the evaluating physician's assessment of CNV leakage on the FA images. Active PDT treatment was administered according to the Visudyne prescribing information⁸ (i.e., the physician should reevaluate the patient every 3 months, and if CNV leakage is detected on FA then standard fluence PDT should be repeated). After careful review of the 12-month data, the study protocol was amended to allow all patients to receive active ranibizumab injections if they had not yet completed their month 23 visit (the last possible injection visit). Double-masking was maintained. Patients in the active PDT/sham ocular injection arm who participated in the amendment received monthly injections of 0.3 mg ranibizumab for the remainder of the trial, whereas patients in the ranibizumab groups who participated continued to receive ranibizumab according to their original randomization (0.3 or 0.5 mg). Active or sham PDT was no longer administered to patients who participated in the amendment but was continued (if needed) per randomization in patients who did not.

Best-corrected VA measured per the study protocol (i.e., measured with Early Treatment Diabetic Retinopathy Study charts at a starting distance of 2 m and using a standardized refraction and testing protocol) and CNV lesion characteristics (based on FA and fundus photography) were assessed at the regularly scheduled study visits. Key FA evaluations were the area of classic CNV, total lesion area, total area of CNV, and total area of leakage from CNV.

Intraocular pressure measurement (before and 60 ± 10 minutes after each study treatment) and indirect ophthalmoscopy and slit-lamp examination (before each study treatment) were performed. The incidence and severity of ocular and nonocular (systemic) adverse events and systemic immunoreactivity (i.e., the presence of serum antibodies against ranibizumab) were assessed.

Efficacy end points were evaluated using an intent-to-treat analysis for randomized patients on the basis of their original treatment assignment. Missing data were imputed using the last-observation-carried-forward method and compared for consistency with those obtained using observed data. All available data were included in analyses of efficacy end points for year 2, including those that occurred after ranibizumab treatment initiation in patients randomized to PDT who crossed over to ranibizumab as part of the protocol amendment.

The primary efficacy end point was the proportion of patients who at 12 months lost fewer than 15 letters (~3 lines) from baseline VA in the study eye. The proportion of patients who lost fewer than 15 letters from baseline at 24 months was a secondary efficacy end point. Other prespecified secondary VA end points assessed at 12 months and 24 months included the mean change from baseline (letters), proportion of patients who gained 15 or more letters from baseline, and proportion of patients with a

Snellen equivalent of 20/200 or worse. Severe VA loss (30 letters [\sim 6 lines] or more from baseline) was an exploratory efficacy end point. Prespecified secondary end points involving characteristics of the CNV lesion at months 12 and 24 were mean changes from baseline in the area of the classic CNV component and the total area of leakage from CNV (including leakage and intense progressive RPE staining). Mean changes in the area of CNV and the area of the entire lesion were exploratory efficacy end points.

Visual acuity outcomes were compared between each ranibizumab dose group and the control group with stratification by baseline VA score (<45 letters vs. ≥ 45 letters). Binary VA end points were analyzed using the Cochran chi-square test,⁹ and the mean change from baseline was analyzed using the *t* test from an analysis of variance model. The mean changes from baseline to month 24 in the CNV lesion characteristics were compared between each ranibizumab dose group and the control group using the *t* test from a stratified, covariate-adjusted analysis of covariance model, with baseline VA score as the stratification variable and baseline value of the corresponding end point as a covariate. The percentage of patients with CNV leakage was compared between groups at month 24 using the Pearson chi-square test.

The main analyses comparing adverse events in the treatment groups were performed using all data for the entire study period, except for patients randomized to PDT who crossed over to ranibizumab as part of the protocol amendment. For these patients, adverse events data collected after their crossover were excluded from the main summaries and summarized separately.

Results

Patient Disposition

Patient disposition is summarized in Table 1 (available at <http://aaojournal.org>). Of 423 patients enrolled and randomized, 143 were assigned to active PDT and 140 each were assigned to the 2 ranibizumab dose levels. Three patients assigned to 0.3 mg ranibizumab withdrew before starting study treatment, and 1 patient in the 0.5-mg group did not have a baseline VA score. The study was completed by 110 patients (76.9%) in the PDT group, 117 patients (83.6%) in the 0.3-mg ranibizumab group, and 116 patients (82.9%) in the 0.5-mg ranibizumab group. Of those patients who discontinued early from the study, only 3 patients (2.1%), 1 patient (0.7%), and 3 patients (2.1%) from the PDT, 0.3-mg, and 0.5-mg groups, respectively, were reported as having been discontinued because of "loss to follow-up." Other reasons for early discontinuation as reported by investigators on the case report form (i.e., death, adverse event, patient's decision, physician's decision, patient noncompliance, patient's condition mandated other therapeutic intervention) were similarly distributed among the treatment groups, with the exception of discontinuation because of "patient's decision," which was more frequent among patients in the PDT group (17/143, 11.9%) than in the 0.3-mg (6/140, 4.3%) and 0.5-mg (8/140, 5.7%) ranibizumab groups.

Baseline Patient Characteristics

Demographic and baseline characteristics of the patients, summarized in Table 2 (available at <http://aaojournal.org>), were well balanced among the treatment groups. Although only patients with predominantly classic CNV, based on initially expedited assessment by the central reading center, were to be enrolled, the central reading center subsequently categorized a few patients in each treatment arm (2 in the PDT group, 6 in the 0.3-mg group, and 5 in the 0.5-mg group) as having minimally classic or occult with no classic CNV lesions; these patients were included in all analyses.

Study Treatment Exposure

The mean number of ranibizumab injections administered during the 2-year treatment period was 21.5 in the 0.3-mg group and 21.3 in the 0.5-mg group. Patients in the PDT group received a mean of 19.2 sham ocular injections. Including the required administration on day 0, active PDT was administered a mean of 3.8 times in the PDT group and sham PDT was administered a mean of 2.2 and 1.9 times in the 0.3-mg and 0.5-mg ranibizumab groups, respectively, during the 24-month study period. This calculation for the active PDT group includes patients who crossed over to ranibizumab (and thus became ineligible for further PDT) as part of the protocol amendment. Ranibizumab exposure and treatment results for the patients in the PDT group who crossed over are discussed below.

Starting as early as month 18, 50 of the 143 patients randomized to the PDT group (35%) crossed over to receive monthly injections of 0.3 mg ranibizumab for the remainder of the treatment period. Patients could receive up to 6 ranibizumab injections if crossover occurred at month 18 or 1 injection if crossover occurred at month 23. The 50 patients who crossed over received a mean of 3.3 ranibizumab injections.

Visual Acuity End Points

Visual acuity outcomes results, which include data from those patients who crossed over (but analyzed according to their randomized treatment assignment) are summarized in Table 3. (An additional table, Table 4 available at <http://aaojournal.org>, provides a frequency distribution of changes in VA relative to baseline in the study eye at month 24.) As previously reported by Brown et al,⁶ the study met its objectives for the primary VA efficacy end point and all secondary VA and FA end points at the end of the first treatment year (i.e., each of the ranibizumab groups was superior to the PDT group for each end point). All second-year efficacy objectives (both VA and FA) concerning secondary end points were also met (the primary analysis for VA end points was at the end of the first year). A statistically significant and clinically meaningful effect of ranibizumab on VA was seen in all VA end points at month 24. Statistical analyses performed using observed data were consistent with the results using the last-observation-carried-forward method described above (i.e., $P < 0.0001$ for all treatment comparisons vs. PDT using either method).

At month 24, 90.0% of patients in the 0.3-mg ranibizumab group and 89.9% of patients in the 0.5-mg ranibizumab group had lost <15 letters from baseline VA, compared with 65.7% of patients in the PDT group. A gain of 15 or more letters from baseline VA was seen in 34.3% of patients in the 0.3-mg ranibizumab group and 41.0% of patients in the 0.5-mg ranibizumab group, compared with 6.3% of patients in the PDT group. The mean change in VA over the 24-month treatment period is shown in Figure 1. On average, VA had improved from baseline by 8.1 letters in the 0.3-mg group and 10.7 letters in the 0.5-mg group at month 24, compared with a mean decline of 9.8 letters in the PDT group. The superior VA benefit of ranibizumab compared with PDT was statistically significant as early as month 1.

At month 24, the percentage of patients with a VA Snellen equivalent of 20/200 or worse was significantly higher in the PDT group (60.8%) than in the ranibizumab groups (22.9% in the 0.3-mg group and 20.0% in the 0.5-mg group; $P < 0.0001$ vs. PDT). Only 1.4% of patients in the 0.3-mg group and none of the patients in the 0.5-mg group experienced severe vision loss (loss ≥ 30 letters; an exploratory end point) compared with baseline, whereas 16.1% of patients in the PDT group had severe vision loss at month 24.

Table 3. Key Visual Acuity Outcomes Relative to Baseline in the Study Eye at Month 12 and Month 24

Efficacy Outcome	Verteporfin PDT (n = 143)	Ranibizumab 0.3 mg (n = 140)	Ranibizumab 0.5 mg (n = 140)
Lost <15 letters—n (%)*			
Month 12 [†]	92 (64.3)	132 (94.3)	134 (96.4)
Month 24	94 (65.7)	126 (90.0)	125 (89.9)
Lost ≥30 letters—n (%)*			
Month 12	19 (13.3)	0	0
Month 24	23 (16.1)	2 (1.4)	0
Snellen VA 20/200 or worse—n (%)			
Baseline*	46 (32.2)	35 (25.0)	32 (23.0)
Month 12	86 (60.1)	31 (22.1)	23 (16.4)
Month 24	87 (60.8)	32 (22.9)	28 (20.0)
Gained ≥0 letters—n (%)*			
Month 12	43 (30.1)	104 (74.3)	108 (77.7)
Month 24	41 (28.7)	109 (77.9)	108 (77.7)
Gained ≥15 letters—n (%)*			
Month 12	8 (5.6)	50 (35.7)	56 (40.3)
Month 24	9 (6.3)	48 (34.3)	57 (41.0)
Gained ≥30 letters—n (%)*			
Month 12	0	9 (6.4)	17 (12.2)
Month 24	3 (2.1)	12 (8.6)	20 (14.4)
Change from baseline (letters)*			
Month 12			
Mean (SD)	−9.5 (16.4)	8.5 (14.6)	11.3 (14.6)
Month 24			
Mean (SD)	−9.8 (17.6)	8.1 (16.2)	10.7 (16.5)

PDT = photodynamic therapy; SD = standard deviation; VA = visual acuity.

NOTE: $P < 0.0001$ for all comparisons of each ranibizumab dose group with the verteporfin PDT group with the exception of Gained ≥30 letters, where at month 12 $P = 0.0018$ for the 0.3-mg ranibizumab group, and at month 24 $P = 0.0132$ and $P = 0.0001$ for the 0.3-mg and 0.5-mg ranibizumab groups, respectively.

*For ranibizumab 0.5-mg group, the number of patients with observations is 139.

[†]Primary efficacy endpoint.

Angiographic End Points

Persistent, statistically significant beneficial effects of ranibizumab on FA-assessed lesion characteristics were also demonstrated at the end of the second study year (Table 5). At month 24, the total area of lesion, on average, remained essentially stable in the ranibizumab groups, increasing from baseline by 0.52 disc areas (DA) and 0.39 DA in the 0.3-mg and 0.5-mg groups, respectively. However, in the PDT group, the area increased by 2.89 DA ($P < 0.0001$ for each dose group vs. PDT). At month 24, the total area of CNV, on average, also remained essentially stable in the ranibizumab groups, increasing from baseline by 0.33 DA and 0.27 DA in the 0.3-mg and 0.5-mg groups, respectively. In contrast, in the PDT group, the area increased by 1.60 DA ($P < 0.0001$ for each dose group vs. PDT). At month 24, the mean area of classic CNV had decreased from baseline by 0.57 DA and 0.72 DA in the 0.3-mg and 0.5-mg groups, respectively; in the PDT group, it had increased by 0.41 DA ($P < 0.0001$, vs. PDT). On average, although the area of classic CNV decreased from baseline in the ranibizumab groups, the area of occult CNV with no classic component increased (by 0.91 DA in the 0.3-mg group and by 0.99 DA in the 0.5-mg group), resulting in small mean increases in the total area of CNV.

The total area occupied by other lesion components showed small mean increases in the ranibizumab groups, reflecting mean increases in the area of subretinal fibrous tissue (or fibrin) or disciform scar and area of atrophic scar, mean changes in the area of blood that was part of the lesion, and negligible mean changes in the area of serous pigment epithelial detachment (data not shown). These changes in the total area of CNV and the area of other lesion components with no CNV account for the small overall mean increase from baseline in the total area of the entire neovascular lesion.

At month 24, the total area of leakage from CNV plus intense progressive RPE staining, on average, had decreased from baseline by 2.23 DA and 2.37 DA in the 0.3-mg and 0.5-mg groups, respectively, and had decreased by 0.78 DA in the verteporfin PDT group ($P < 0.0001$, vs. PDT). The percentage of patients with leakage from CNV plus intense progressive RPE staining declined in all 3 treatment groups from month 12 to month 24, but the percentage of patients whose lesions were still leaking at month 24 was significantly smaller in the ranibizumab-treated groups ($P < 0.0001$, vs. PDT). Both the mean and standard deviation for the total area of leakage from CNV were identical (to 2 decimal places) with those for the total area of leakage from CNV plus intense progressive RPE staining, indicating that the mean area of intense progressive RPE staining was small.

Patients Who Crossed Over to Ranibizumab

Demographic and baseline characteristics of patients in the PDT group who switched to ranibizumab treatment were comparable to those of patients in the PDT group who did not switch to ranibizumab treatment (Table 2, available at <http://aaojournal.org>). Efficacy outcomes for patients who did and did not cross over are summarized in Table 6 (available at <http://aaojournal.org>). After 18 months or longer in the PDT group, patients who switched to ranibizumab treatment, on average, maintained the VA measured just before crossover. The overall mean change in VA was +0.2 letters (median change, 0 letters; range, −20 to +24 letters) at month 24. The 33 patients who received 3 or more ranibizumab injections after crossover had a mean change in VA of −0.6 letters (median change, 0 letters; range, −20 to +24 letters). At month 24, patients who crossed over to ranibizumab had a mean decrease of 5.7 letters compared with a mean decrease of 12.1 letters for patients who did not cross over. There were no notable differences between these PDT groups in the mean changes in total area of lesion, total area of CNV, and area of classic CNV at month 24. However, patients who crossed over had better control of leakage from CNV at month 24 (mean decrease of 1.9 DA in the total area of leakage from CNV plus intense progressive RPE staining and 40% of patients with leakage from CNV plus intense progressive RPE staining) compared with patients who did not cross over (mean decrease of 0.2 DA and 79% of patients with leakage). Patients randomized to PDT who crossed over to ranibizumab as part of the amendment were, on average, doing better on their original treatment regimen both in VA measures and in control of leakage from CNV than were patients who did not cross over (see month 12 and month 18 outcomes in Table 6, available at <http://aaojournal.org>).

Adverse Events

The cumulative rates of key ocular and nonocular adverse events during the 2-year study period are summarized in Table 7. Overall, there was no imbalance among the 3 treatment groups in the rates of serious and nonserious ocular adverse events in the study eye. The percentages of patients with any serious ocular adverse event in the study eye were similar among the PDT (7.7%), 0.3-mg ranibizumab (7.3%), and 0.5-mg ranibizumab (9.3%) groups.

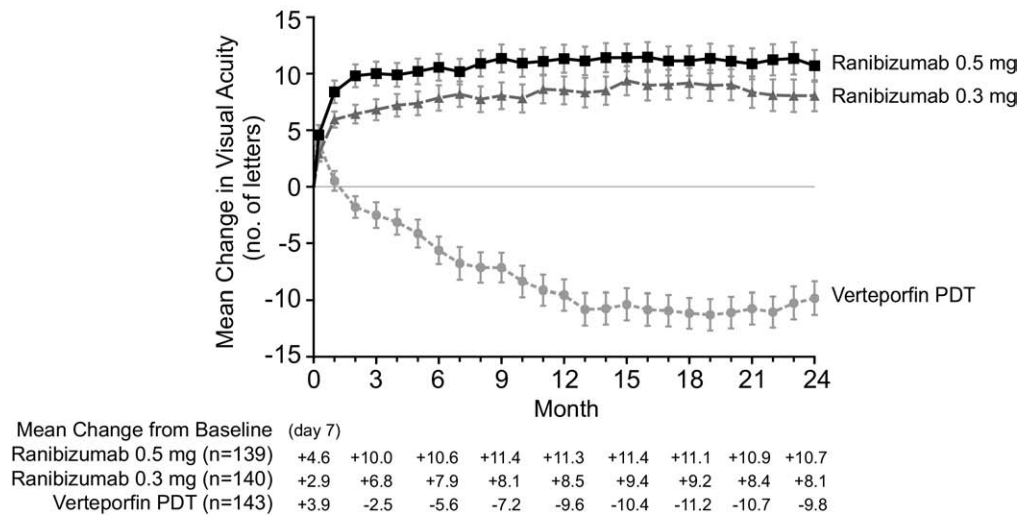


Figure 1. Mean change from baseline visual acuity (VA) score (letters) over time. Vertical bars represent ± 1 standard error of the mean. The mean change at some visits in the first year differed slightly from those previously reported⁶ because the present analysis is based on the final data. $P < 0.001$ for all comparisons versus verteporfin photodynamic therapy (PDT) at each month. Pairwise analysis of variance models adjusting for VA score at day 0 (< 45 letters vs. ≥ 45 letters) were used to analyze mean VA change from baseline at each monthly assessment. The last-observation-carried-forward method was used to impute missing data. All tests were 2-sided.

Serious ocular adverse events considered to be potentially related to intravitreal ranibizumab treatment include endophthalmitis, uveitis, vitreous hemorrhage, rhegmatogenous retinal detachment, retinal tear, and lens damage. In the combined ranibizumab groups, “presumed” endophthalmitis (i.e., including the patient in Table 7 whose adverse event was reported as “serious uveitis,” but was treated with systemic antibiotics) in the study eye occurred in 3 of 277 patients (1.1%) in the pooled ranibizumab groups and in no patients in the PDT group. The rate of presumed endophthalmitis in the study eye per injection was 3 of 5921 injections (0.05%) in the pooled ranibizumab groups; all 3 of these patients had gains in VA at month 24 compared with baseline

(+13, +26, and +32 letters, respectively). No patient other than the one mentioned above experienced uveitis classified as serious. Vitreous hemorrhage was reported in 2 of 277 patients (0.7%) in the pooled ranibizumab groups versus 0 of 143 patients in the PDT group. Rhegmatogenous retinal detachment occurred in 2 patients (0.7%) in the pooled ranibizumab groups and 1 patient (0.7%) in the PDT group; the rates per ocular injection were 2 of 2571 (0.07%) in the PDT group (sham injection) and 2 of 5921 (0.03%) in the pooled ranibizumab groups.

The percentage of patients who experienced any serious or nonserious adverse event of intraocular inflammation (i.e., iritis, iridocyclitis, vitritis, uveitis, anterior-chamber inflammation, or

Table 5. Anatomical Characteristics in the Study Eye at Month 24

Month 24 Outcome Measure	Verteporfin PDT (n = 143)	Ranibizumab	
		0.3 mg (n = 140)	0.5 mg (n = 140)
Change in total area of lesion (DA)			
Mean (SD)	2.89 (3.33)	0.52 (1.34)	0.39 (1.34)
95% CI of the mean	(2.34, 3.44)	(0.30, 0.75)	(0.16, 0.61)
Change in total area of CNV (DA)			
Mean (SD)	1.60 (2.42)	0.33 (1.21)	0.27 (1.28)
95% CI of the mean	(1.20, 2.00)	(0.13, 0.54)	(0.05, 0.48)
Change in area of classic CNV (DA)			
Mean (SD)	0.41 (2.30)	-0.57 (1.12)	-0.72 (1.12)
95% CI of the mean	(0.03, 0.79)	(-0.76, -0.39)	(-0.91, -0.54)
Change in total area of leakage from CNV + intense progressive RPE staining (DA)			
Mean (SD)	-0.78 (3.44)	-2.23 (2.09)	-2.37 (2.14)
95% CI of the mean	(-1.35, -0.21)	(-2.58, -1.88)	(-2.72, -2.01)
Patients with leakage from CNV + intense progressive RPE staining	65.0%	37.9%	39.3%

CI = confidence interval; CNV = choroidal neovascularization; DA = disc areas; PDT = photodynamic therapy; SD = standard deviation; RPE = retinal pigment epithelium.

NOTE: $P < 0.0001$ for all comparisons of each ranibizumab dose group with the verteporfin PDT group.

Table 7. Key Adverse Event Findings: Cumulative for 2 Years of ANCHOR Study

	Verteporfin PDT (n = 143)	Ranibizumab 0.3 mg (n = 137)	Ranibizumab 0.5 mg (n = 140)
Key Serious Ocular Adverse Events—no. (%)			
Presumed endophthalmitis*	0	0	3 (2.1)
Uveitis	0	0	1 (0.7)*
Rhegmatogenous retinal detachment	1 (0.7) [†]	2 (1.5)	0
Retinal tear	0	0	1 (0.7)
Vitreous hemorrhage	0	2 (1.5)	0
Lens damage	0	0	0
Most Severe Ocular Inflammation, Regardless of Cause (Slit-Lamp Examination)—no. (%)			
1+	1 (0.7)	3 (2.2)	9 (6.4)
2+	0	2 (1.5)	0
3+	0	2 (1.5)	4 (2.9)
4+	0	1 (0.7)	1 (0.7)
Key Nonocular Adverse Events—no. (%)			
Treatment-emergent hypertension	23 (16.1)	13 (9.5)	17 (12.1)
Key arterial thromboembolic events (nonfatal)			
Myocardial infarction	2 (1.4)	1 (0.7)	5 (3.6)
Cerebrovascular accident	2 (1.4)	3 (2.2) [‡]	0
Death			
Vascular (APTC criteria)	5 (3.5) [§]	5 (3.6)	3 (2.1)
Nonvascular [#]	3 (2.1)	2 (1.5)	2 (1.4)
Nonocular hemorrhage			
Total (serious or nonserious)**	7 (4.9)	12 (8.8)	13 (9.3)
Reported as a serious adverse event	1 (0.7)	4 (2.9)	3 (2.1)

ANCHOR = Anti-VEGF Antibody for the Treatment of Predominantly Classic Choroidal Neovascularization in Age-related Macular Degeneration; APTC = Antiplatelet Trialists' Collaboration; PDT = photodynamic therapy.

*Presumed endophthalmitis was defined as cases in which intravitreal or systemic antibiotics were administered. One patient had 2 episodes of intraocular inflammation that were reported as uveitis, but one of the episodes was classified as presumed endophthalmitis because it was treated with systemic antibiotics. In neither of these 2 episodes was a vitreous culture obtained, and neither was treated with intravitreal antibiotics. Vitreous culture was positive for *Staphylococcus epidermidis* for 1 patient, and culture was negative for another patient.

[†]Patient had 2 episodes of rhegmatogenous retinal detachment.

^{*}Includes 1 nonserious adverse event of cerebral ischemia.

[‡]Two patients died after withdrawing from the study because of an adverse event.

^{||}Verteporfin PDT group: deaths due to cardiac arrest, congestive heart failure, and coronary artery disease (1 patient each). Ranibizumab 0.3-mg group: deaths due to cardiac arrest and exacerbation of bradycardia (1 patient each). Ranibizumab 0.5-mg group: deaths due to cardiac failure and worsening of chronic heart failure (1 patient each).

[#]Verteporfin PDT group: deaths due to chronic obstructive pulmonary disease and complications secondary to renal cell carcinoma (1 patient each). Ranibizumab 0.3-mg group: deaths due to respiratory arrest, viral syndrome, and pneumonia (1 patient each). Ranibizumab 0.5-mg group: death due to adult failure to thrive.

**Detailed nonocular hemorrhage adverse events are summarized in Table 8 (available online at <http://aaojournal.org>).

hypopyon) in the study eye was higher in the ranibizumab groups (11.7% in the 0.3-mg group and 17.1% in the 0.5-mg group) than in the PDT group (3.5%). Findings from objective slit-lamp examinations were consistent with the reports of intraocular inflammation adverse events. As in all previous trials of ranibizumab, transient increases in intraocular pressure in the study eye were common in the hour after intravitreal injection of ranibizumab (data not shown).

No traumatic lens damage was reported. A trend for a higher rate of cataract (new or worsened according to the investigator's clinical judgment) in the study eye was seen in the ranibizumab groups (16.8% in the 0.3-mg group, 20.0% in the 0.5-mg group) compared with the PDT group (10.5%); post hoc analysis showed the difference between the 0.5-mg ranibizumab group and the PDT group to be statistically significant ($P = 0.03$, Pearson chi-square test). Cataract surgery was performed during the 24-month study period in 1 of 143 patients, 5 of 137 patients, and 5 of 140 patients in the PDT, 0.3-mg, and 0.5-mg groups, respectively. Visual acuity changes at month 24 in patients who were phakic at baseline and became pseudophakic during the study period were not notably

different from those in the respective treatment groups overall (data not shown).

Among the 50 patients randomized to PDT who switched to ranibizumab as part of the protocol amendment, none experienced a serious adverse event in the study eye after their crossover.

Overall, there was no imbalance among the 3 treatment groups in the rates of serious nonocular adverse events, including those known to be potentially associated with systemic administration of anti-VEGF agents in the cancer treatment setting. The rates of arterial thromboembolic events (defined using Antiplatelet Trialists' Collaboration criteria¹⁰) were similar across the PDT (4.2%), 0.3-mg ranibizumab (4.4%), and 0.5-mg ranibizumab (5.0%) groups. Although the rate of Antiplatelet Trialists' Collaboration arterial thromboembolic events in the 0.5-mg group (3.6%) was slightly higher than in the PDT and 0.3-mg groups (2.1% and 2.2%, respectively) during the first treatment year, it was slightly lower than in the other 2 groups during the second treatment year: 1.6% (2/128) of patients in the 0.5-mg group compared with 2.4% (3/127) in the 0.3-mg group and 2.3% (3/128) in the PDT group. None of these differences was statistically significant (Fisher exact

test). No deaths from myocardial infarction or cerebrovascular accident occurred during the study. Rates of nonfatal cerebrovascular accident were 1.4%, 2.2%, and 0%, in the PDT, 0.3-mg, and 0.5-mg groups, respectively.

Four (8.0%) of the 50 patients randomized to PDT who switched to ranibizumab as part of the protocol amendment experienced a serious nonocular adverse event during the crossover period. These serious adverse events were as follows and occurred in 1 patient (2.0%) each: aortic aneurysm, atrial fibrillation, carotid artery stenosis, coronary artery disease, fall, femur fracture, and gastric ulcer hemorrhage.

Hypertension adverse events were not more common in the ranibizumab groups than in the PDT group. However, nonocular hemorrhage was more common in the ranibizumab groups (8.8% in the 0.3-mg group, 9.3% in the 0.5-mg group, vs. 4.9% in the PDT group), although these differences were not statistically significant (Pearson chi-square test). Table 8 (available online at <http://aaojournal.org>) shows the rates of nonserious and serious nonocular hemorrhagic events by treatment group. The incidence of serious nonocular hemorrhage was also slightly higher in the ranibizumab groups (2.9% in the 0.3-mg group, 2.1% in the 0.5-mg group, vs. 0.7% in the PDT group). Serious hemorrhages in the ranibizumab-treated groups included gastrointestinal hemorrhage (4 patients), traumatic subdural hematoma (2 patients), and duodenal ulcer hemorrhage (1 patient). The temporal pattern of these events in relation to ranibizumab dosing did not suggest a causal association. No ranibizumab-treated patient experienced proteinuria.

Systemic Immunoreactivity

Serum samples from patients demonstrated systemic immunoreactivity to ranibizumab in a small number of patients in all 3 treatment groups at the baseline measurement at screening (2 in the PDT group, 4 in the 0.3-mg group, 1 in the 0.5-mg group). No increases in the percentage of patients with immunoreactivity to ranibizumab were seen in the PDT group or the 0.3-mg group. The 0.5-mg group experienced an increase in the percentage of patients with immunoreactivity at the month 24 visit relative to baseline and relative to the other treatment groups. At month 24, 8.2% of patients in the 0.5-mg group exhibited immunoreactivity in their serum samples. Ranibizumab-treated subjects who were immunoreactive at baseline or during treatment had a higher incidence of intraocular inflammation than other ranibizumab-treated patients. Of the 3 ranibizumab-treated patients who experienced presumed endophthalmitis, only the patient whose inflammation was reported as severe, serious uveitis but was treated with systemic antibiotics exhibited immunoreactivity during the treatment period (months 6, 12, and 24); this patient also tested positive for immunoreactivity at screening (i.e., before ranibizumab treatment). Immunoreactivity showed no notable relationship to nonocular adverse events identified for the immunoreactivity analysis, and patients who were immunoreactive had VA results similar to those of other patients.

Discussion

Ranibizumab administered as monthly intravitreal injections of 0.3 mg or 0.5 mg over 24 months was effective, and superior to verteporfin PDT, in maintaining or improving VA in patients with predominantly classic subfoveal neovascular AMD. The VA benefit from ranibizumab was both rapid and sustained: The superiority of ranibizumab to PDT was evident by 1 month after starting treatment, increased to

a plateau by the end of the first year, and then persisted through month 24. This represents a major breakthrough in the treatment of predominantly classic CNV secondary to AMD. Studies of the natural history of predominantly classic lesions before the 2000 approval of verteporfin PDT showed that at 2 years only 31% of patients lost fewer than 15 letters from their baseline VA and few patients (4%) gained at least 15 letters.^{4,5} The proportion of patients with VA worse than Snellen 20/200 increased from 19.5% at baseline to 75.7% by 3 years.¹¹ Verteporfin PDT, approved in the United States for treatment of predominantly classic neovascular AMD in April 2000, brought an important advance: The TAP study demonstrated that with this treatment 59% of patients had lost fewer than 15 letters from baseline and 9% had actually gained 15 letters or more at 2 years.^{4,5} The ANCHOR trial results for patients in the PDT group are consistent with the TAP data, with 66% of patients losing fewer than 15 letters and 6% gaining 15 letters or more by month 24. However, in the present double-masked, randomized, active-treatment-controlled trial, monthly treatment with ranibizumab dramatically improved the VA results of patients with predominantly classic CNV, with 90% of patients in the 0.5-mg dose group losing fewer than 15 letters and more than 40% maintaining a gain of at least 15 letters through 2 years of treatment.

It is interesting that the improvements from baseline in VA outcomes in ranibizumab-treated patients in the ANCHOR study at 2 years are more impressive than those achieved with ranibizumab at 2 years in the similarly designed MARINA study in patients with minimally classic or occult with no classic CNV lesions.⁷ Although the average size of CNV lesions was smaller in the ANCHOR patients than in the MARINA patients, predominantly classic lesions are typically more aggressive and lead to more rapid loss of VA than minimally classic or occult lesions. One explanation for the greater improvement from baseline among ANCHOR patients than among MARINA patients is that predominantly classic lesions are diagnosed earlier than occult lesions, because the more rapid visual decline typically seen with this type of lesion is more likely to compel a patient to consult a physician; this allows earlier treatment with subsequent improved VA results despite the greater aggressiveness of the disease. In addition, recent VA loss associated with a rapidly progressing predominantly classic CNV may still be partially reversible when treated before photoreceptors suffer irreversible damage. In contrast, VA lost several months earlier because of slowly progressing occult CNV may ultimately reflect an irreversible loss of photoreceptors, with little opportunity for as great an improvement in VA with whatever treatment chosen. A second possible explanation is that the baseline VA of patients with predominantly classic lesions is lower than that of patients with minimally classic or occult with no classic CNV lesions, providing room for greater improvement.

Better VA outcome and better control of leakage from CNV at month 24 were observed in the 50 patients randomized to PDT who switched to ranibizumab after the protocol amendment compared with patients who did not switch to ranibizumab. However, although the better outcomes in patients who crossed over may have diluted the overall poor

outcomes in the PDT group, this did not appear to be due to the ranibizumab treatment during crossover but to factors that occurred before crossover. Interpretation of the post-crossover VA outcomes in the patients in the PDT group who switched to ranibizumab is complicated by the observation that they had better VA outcomes and better control of leakage from CNV than did patients in the PDT group who did not cross over even before switching treatments. It is possible that patients who stayed in the study long enough to have the opportunity to cross over may have been those who were doing well with PDT. Compared with patients who were randomized to ranibizumab treatment, patients randomized to PDT who switched to ranibizumab during the second year did not appear to benefit from ranibizumab as much or as early during their treatment period (range, 1–6 injections). In these 50 patients, VA was maintained on average, but not improved. This finding supports the argument that treatment with ranibizumab early in the course of the disease may recover recently lost letters but will have little impact on irreversible damage incurred 1 year or more previously. Alternatively, multiple standard fluence PDT treatments may cause irreversible retinal or choroidal damage that precludes VA improvements.¹²

Outcomes in the ANCHOR study assessed by FA were consistent with the VA outcomes. On average, lesion characteristics assessed by FA were improved with ranibizumab at 12 and 24 months. Overall, the treatment benefit of ranibizumab over verteporfin PDT at month 24 was similar to that at month 12 for the mean changes from baseline in area of classic CNV, total area of lesion, and total area of CNV, and was smaller for the mean change from baseline in the total area of leakage from CNV. A significantly smaller percentage of ranibizumab-treated patients than PDT-treated patients continued to exhibit leakage from CNV in the study eye at 24 months.

Ranibizumab administered as monthly intravitreal injections was well tolerated for up to 24 months in the ANCHOR trial, with an adverse events profile similar to that observed in the MARINA study. The percentages of ranibizumab-treated patients experiencing serious ocular adverse events, or any of the nonocular adverse events potentially associated with systemic anti-VEGF therapy reported here, were low. As in previous ranibizumab clinical trials, intraocular inflammation (mostly mild) and transient post-injection increases in intraocular pressure were common but manageable. There was an apparent trend for an increased incidence of cataract in the ranibizumab groups compared with the PDT group, which was statistically significant at the 0.5-mg dose. In the MARINA study, both ranibizumab-treated patients and patients in the sham-injection control group had rates of cataract slightly less than 16%, so the rate of 10.5% in the PDT group in the ANCHOR study was lower than expected. However, the possibility that intravitreal injection of ranibizumab accelerates progression of cataract cannot be ruled out.

Ranibizumab-treated and ranibizumab-naïve (control) patients who completed the pivotal phase III ANCHOR and MARINA studies, as well as patients who completed a 2-year phase I/III study comparing combination treatment with ranibizumab and verteporfin PDT versus verteporfin

PDT alone in patients with predominantly classic CNV lesions (the RhuFab V2 Ocular Treatment Combining the Use of Visudyne to Evaluate Safety [FOCUS] study), are currently being followed while receiving ranibizumab treatment in an open-label, 3-year extension study designated HORIZON. In the extension study, patient follow-up and retreatment are flexible and based on individual patient response and investigator discretion. The outcome of this longer-term evaluation of the efficacy and adverse events profile of ranibizumab in treatment of AMD-associated CNV lesions, using a more flexible, individually adjusted schedule of ranibizumab dosing, will be of great interest.

Acknowledgments. The authors thank Linda Phillips, PhD, Genentech, Inc., for writing and editorial assistance.

References

1. Ali F, Chan WC, Stevenson MR, et al. Morphometric analysis of angiograms of exudative lesions in age-related macular degeneration. *Arch Ophthalmol* 2004;122:710–5.
2. Pauleikhoff D. Neovascular age-related macular degeneration: natural history and treatment outcomes. *Retina* 2005;25:1065–84.
3. Lafaut BA, Bartz-Schmidt KU, Vanden Broecke C, et al. Clinicopathological correlation in exudative age related macular degeneration: histological differentiation between classic and occult choroidal neovascularisation. *Br J Ophthalmol* 2000;84:239–43.
4. Treatment of Age-Related Macular Degeneration With Photodynamic Therapy Study Group. Verteporfin therapy of subfoveal choroidal neovascularization in patients with age-related macular degeneration: additional information regarding baseline lesion composition's impact on vision outcomes—TAP report no. 3. *Arch Ophthalmol* 2002;120:1443–54.
5. Treatment of Age-Related Macular Degeneration With Photodynamic Therapy Study Group. Photodynamic therapy of subfoveal choroidal neovascularization in age-related macular degeneration with verteporfin: two-year results of 2 randomized clinical trials—TAP report 2. *Arch Ophthalmol* 2001;119:198–207.
6. Brown DM, Kaiser PK, Michels M, et al. ANCHOR Study Group. Ranibizumab versus verteporfin for neovascular age-related macular degeneration. *N Engl J Med* 2006;355:1432–44.
7. Rosenfeld PJ, Brown DM, Heier JS, et al. MARINA Study Group. Ranibizumab for neovascular age-related macular degeneration. *N Engl J Med* 2006;355:1419–31.
8. Visudyne [package insert]. East Hanover, NJ: Novartis Pharmaceuticals Corp; 2007. Available at: <http://www.pharma.us.novartis.com/product/pi/pdf/visudyne.pdf>. Accessed October 13, 2008.
9. Cochran WG. Some methods for strengthening the common chi-square tests. *Biometrics* 1954;10:417–51.
10. Antiplatelet Trialists' Collaboration. Collaborative overview of randomised trials of antiplatelet therapy—I: Prevention of death, myocardial infarction, and stroke by prolonged antiplatelet therapy in various categories of patients. *BMJ* 1994;308:81–106.
11. Wong TY, Chakravarthy U, Klein R, et al. The natural history and prognosis of neovascular age-related macular degeneration: a systematic review of the literature and meta-analysis. *Ophthalmology* 2008;115:116–26.
12. Schlotzer-Schrehardt U, Viestenz A, Naumann GO, et al. Dose-related structural effects of photodynamic therapy on choroidal and retinal structures of human eyes. *Graefes Arch Clin Exp Ophthalmol* 2002;240:748–57.

Footnotes and Financial Disclosures

Originally received: June 3, 2008.

Final revision: September 25, 2008.

Accepted: October 15, 2008.

Manuscript no. 2008-678.

¹ Vitreoretinal Consultants, Methodist Hospital, Houston, Texas.

² Retina Care Specialists, Palm Beach Gardens, Florida.

³ Cole Eye Institute, Cleveland Clinic Foundation, Cleveland, Ohio.

⁴ Ophthalmic Consultants of Boston, Boston, Massachusetts.

⁵ Genentech, Inc., South San Francisco, California.

A list of the principal investigators of the ANCHOR Study Group (Appendix 1) is available at <http://aojournal.org>.

Financial Disclosure(s):

The author(s) have made the following disclosure(s):

David Brown has received consulting fees from Genentech, Regeneron, Alcon, and Allergan and lecture fees from Genentech, Regeneron, and Alcon; Peter Kaiser has received consulting fees from Genentech, Novartis, and QLT; Jeffrey Heier has received consulting fees from Genentech, Regeneron, Pfizer, Jerini Ophthalmics, and Neo Vista, lecture fees from Regeneron, Jerini Ophthalmics, and Neo Vista, and financial support from Genentech, Regeneron, Pfizer, Jerini Ophthalmics, Neo Vista, and Alcon; Judy Sy and Tsontcho Ianchulev are employees of Genentech and hold Genentech stock; Mark Michels had no financial disclosures. Linda Phillips is an employee of and stockholder in Genentech.

This study was funded by Genentech and Novartis Pharma.

Correspondence:

David M. Brown, MD, Vitreoretinal Consultants, 6560 Fannin, Suite 750, Houston, TX 77030. E-mail: dmbmd@houstonretina.com.

Appendix 1. ANCHOR Study Group

The ANCHOR Study Group comprises the following principal investigators: Thomas Aaberg, Associated Retinal Consultants, Grand Rapids, MI; Prema Abraham, BH Regional Eye Institute, Rapid City, SD; Levant Akduman, St. Louis University Eye Institute, St. Louis, MO; D. Virgil Alfaro, III, Retina Consultants of Charleston, Charleston, SC; Andrew Antoszyk, Southeast Clinical Research Associates, Charlotte, NC; Jennifer Arnold, Marsden Eye Research, Parramatta, Australia; Carl Awh, Retina Vitreous Associates, Nashville, TN; Paul Beer, New Lions Eye Institute, Slingerlands, NY; Jonathan Belmont, Retina Diagnostic & Treatment, Philadelphia, PA; Brian Berger, Retina Research Center, Austin TX; Daniel Berinstein, Retina Group of Washington, Fairfax, VA; Robert Bhisitkul, University of California at San Francisco, School of Medicine, Dept. of Ophthalmology, San Francisco, CA; David Boyer, Retina-Vitreous Associates, Beverly Hills, CA; William Bridges, Western Carolina Retinal Associates, Asheville, NC; H. Logan Brooks, Jr., Southern Vitreoretinal Associates, Tallahassee, FL; David Brown, Vitreoretinal Consultants, Houston, TX; Thomas Ciulla, Indianapolis, IN; W. Lloyd Clark, Palmetto Retina Center, Columbia, SC; Thomas Connor, Medical College of Wisconsin, Milwaukee, WI; Scott Cousins, Bascom Palmer Eye Institute, Palm Beach Gardens, FL; Francois Devin, Clinique Monticelli, Marseille, France; William Dunn, Florida Retina Institute, Daytona Beach, FL; Alexander Eaton, Retina Health Center, Fort Myers, FL; Dean Sharon Fekrat, Duke University Eye Center, Durham, NC; Christian Foja, Universitätsklinikum Leipzig, Leipzig, Germany; Bradley Foster, New England Retina Consultants, West Springfield, MA; Alain Gaudric, Hôpital Lariboisière, Paris, France; Mark Gilles, Save Sight Institute, Sydney, Australia; David Glaser, Retina Associates of St. Louis, Florissant, MO; Bernard Godley, Retina Specialists, Desoto, TX; Victor Gonzalez, Valley Retina Institute, P.A., McAllen, TX; Roy Goodart, Rocky Mountain Retina Consultants, Salt Lake City, UT; Robyn Guymer, University of Melbourne, Centre for Eye Research Australia, East Melbourne, Australia; Lawrence Halperin, Retina Vitreous Consultants, Fort Lauderdale, FL; Jeffrey Heier, Ophthalmic Consultants of Boston, Boston, MA; Frank Holz, Universitätsklinikum Bonn, Bonn, Germany; Baker Hubbard, Emory University, Atlanta, GA; Henry Hudson, Retina Centers, P.C., Tucson, AZ; Darma Ie, Delaware Valley Retina Associates, Lawrenceville, NJ; Mark Johnson, University of Michigan, Ann Arbor, MI; Antonia Jousseaume, Universitätsklinikum Köln, Köln, Germany; Peter Kaiser, Cleveland Clinic Foundation, Cole Eye Institute, Cleveland, OH; Baruch Kuppermann, University

of California at Irvine, Irvine, CA; Mark Lomeo, Midwest Retina, Columbus, OH; Christopher MacDonald, University of Texas Health Science Center, Dept. of Ophthalmology, San Antonio, TX; Dennis Marcus, Southeast Retina Center, Augusta, GA; Adam Martidis, Retina Diagnostic & Treatment, Philadelphia, PA; Jose Martinez, Austin Retina Associates, Austin, TX; Donald Maxwell, Jr., Retinal Associates of Oklahoma, Oklahoma City, OK; Tod McMillan, Southeastern Retina Associates, P.C., Knoxville, TN; Mark Michels, Palm Beach Gardens, FL; David Miller, Retina Associates of Cleveland, Beachwood, OH; Paul Michell, Westmead Hospital, Westmead, Australia; Ira Orgel, Retina Vitreous Associates, Toledo, OH; Robert Park, University of Arizona, Tucson, AZ; Matthew Paul, Danbury Eye Physicians and Surgeons, Danbury, CT; Peter Pavan, University of South Florida, Dept. of Ophthalmology, Tampa, FL; Michael Petersen, Cincinnati Eye Institute, Cincinnati, OH; Jay Prenskey, Pennsylvania Retina Specialists, P.C., Camphill, PA; Paul Raskauskas, Retina Consultants of Southwest Florida, Fort Myers, FL; Elias Reichel, New England Eye Center, Boston, MA; Deborah Reid, Retina Associates, P.C., Annapolis, MD; Preston Richmond, Central Florida Retina, Orlando, FL; William Rodden, Retina and Vitreous Center of Southern Oregon, Ashland, OR; Philip J. Rosenfeld, Bascom Palmer Eye Institute, Miami, FL; Paul Runge, Ophthalmic Consultants, Sarasota, FL; Srinivas Satta, Doheny Eye Institute, Los Angeles, CA; Steven Sanislo, California Vitreoretinal Research Center, Menlo Park, CA; Stephen G. Schwartz, Bascom Palmer Eye Institute, Palm Beach Gardens, FL; András Istvan Seres, I. Ophthalmological Clinic, Semmelweis University, Budapest, Hungary; Michael Singer, Medical Center Ophthalmology Associates, San Antonio, TX; Gisele Soubrane, Clinique d'Ophthalmologie, University ParisXII-Créteil, Créteil, France; Petr Soucek, Oční klinika FNKV, Praha, Czech Republic; Walter Stern, Northern California Retina-Vitreous Associates, Mountain View, CA; Glenn Stoller, Ophthalmic Consultants of Long Island, Rockville Centre, NY; John Thompson, Retina Specialists, Towson, MD; David Tom, New England Retina Associates, Hamden, CT; Robert Torti, Retina Specialists, Desoto, TX; Michael Trese, Associated Retinal Consultants, P.C., Royal Oak, MI; Erik van Kuijk, University of Texas Medical Branch, Galveston, TX; Thierry Verstaeten, Allegheny General Hospital, Pittsburgh, PA; Keith Warren, University of Kansas Medical Center, Kansas City, KS; Harold Weiss, Retina Consultants of Michigan, Southfield, MI; Jeffrey Weiss, Retina Associates of South Florida, Margate, FL; Craig Wells, Vitreoretinal Associates, Seattle, WA; Sebastian Wolf, Universitätsklinikum Leipzig, Leipzig, Germany; Kang Zhang, John Moran Eye Center, University of Utah, Salt Lake City, UT.

Table 1. Patient Disposition in ANCHOR Trial

	Verteporfin PDT (no., %)	Ranibizumab 0.3 mg (no., %)	Ranibizumab 0.5 mg (no., %)	Total (no., %)
Enrolled	—	—	—	423 (100)
Randomly assigned to treatment	143 (100)	140 (100)	140 (100)	423 (100)
Received randomized treatment	143 (100)	137 (97.9)	140 (100)	420 (99.3)*
Intent-to-treat patients for efficacy analyses	143 (100)	140 (100)	140 (100)	423 (100)
Included in safety evaluation	143 (100)	137 (97.9)	140 (100)	420 (99.3)
Completed month 12 [†]	127 (88.8)	128 (91.4)	131 (93.6)	386 (91.3)
Completed study	110 (76.9)	117 (83.6)	116 (82.9)	343 (81.1)
Discontinued from study	33 (23.1)	23 (16.4)	24 (17.1)	80 (18.9)
Death	3 (2.1)	5 (3.6)	3 (2.1)	11 (2.6)
Adverse event	6 (4.2)	6 (4.3)	7 (5.0)	19 (4.5)
Lost to follow-up	3 (2.1)	1 (0.7)	3 (2.1)	7 (1.7)
Patient's decision	17 (11.9)	6 (4.3)	8 (5.7)	31 (7.3)
Physician's decision	2 (1.4)	2 (1.4)	1 (0.7)	5 (1.2)
Patient noncompliance	0	3 (2.1)	2 (1.4)	5 (1.2)
Patient's condition mandated other therapeutic intervention	2 (1.4)	0	0	2 (0.5)
Discontinued treatment [‡]	38 (26.6)	28 (20.0)	28 (20.0)	94 (22.2)
Death	3 (2.1)	5 (3.6)	3 (2.1)	11 (2.6)
Adverse event	9 (6.3)	9 (6.4)	10 (7.1)	28 (6.6)
Lost to follow-up	3 (2.1)	1 (0.7)	3 (2.1)	7 (1.7)
Patient's decision	18 (12.6)	9 (6.4)	8 (5.7)	35 (8.3)
Physician's decision	2 (1.4)	2 (1.4)	1 (0.7)	5 (1.2)
Patient noncompliance	0	2 (1.4)	2 (1.4)	4 (0.9)
Patient's condition mandated other therapeutic intervention	3 (2.1)	0	1 (0.7)	4 (0.9)
Eligible to participate in protocol amendment [§]	55 (38.5)	52 (37.1)	51 (36.4)	158 (37.4)
Participated in protocol amendment	50 (35.0)	49 (35.0)	50 (35.7)	149 (35.2)
Crossed over to receive 0.3 mg ranibizumab	50 (35.0)	—	—	50 (35.0)
At month 18	5 (3.5)	—	—	5 (3.5)
At month 19	12 (8.4)	—	—	12 (8.4)
At month 20	7 (4.9)	—	—	7 (4.9)
At month 21	11 (7.7)	—	—	11 (7.7)
At month 22	8 (5.6)	—	—	8 (5.6)
At month 23	7 (4.9)	—	—	7 (4.9)

ANCHOR = Anti-VEGF Antibody for the Treatment of Predominantly Classic Choroidal Neovascularization in Age-related Macular Degeneration; PDT = photodynamic therapy.

*Three patients did not receive the randomly assigned treatment, 1 because of the patient's decision and 2 because of the physician's decision.

[†]Defined as having the VA assessment in study eye at month 12. Patients who missed the month 12 visit but stayed in the study for the second year were not included.

[‡]Some patients remained in the study after treatment discontinuation.

[§]Patients were eligible to participate in the protocol amendment if they were still receiving study treatment when the plan was offered to them.

Table 2. Patient Demographics and Baseline Study Eye Characteristics

Characteristic	Verteporfin PDT			Ranibizumab	
	Overall (n = 143)	No Crossover (n = 93)	Crossover (n = 50)	0.3 mg (n = 140)	0.5 mg (n = 140)
Gender — no. (%)					
Men	64 (44.8)	42 (45.2)	22 (44.0)	73 (52.1)	75 (53.6)
Women	79 (55.2)	51 (54.8)	28 (56.0)	67 (47.9)	65 (46.4)
Race* — no. (%)					
White	140 (97.9)	92 (98.9)	48 (96.0)	137 (97.9)	136 (97.1)
Other	3 (2.1)	1 (1.1)	2 (4.0)	3 (2.1)	4 (2.9)
Age (y)					
Mean (SD)	77.7 (7.8)	78.5 (7.6)	76.3 (7.9)	77.4 (7.5)	76.0 (8.6)
Range	53–95	56–95	53–88	54–97	54–93
Age group — no. (%)					
50–64 y	8 (5.6)	4 (4.3)	4 (8.0)	9 (6.4)	14 (10.0)
65–74 y	35 (24.5)	21 (22.6)	14 (28.0)	28 (20.0)	41 (29.3)
75–84 y	74 (51.7)	48 (51.6)	26 (52.0)	84 (60.0)	64 (45.7)
≥85 y	26 (18.2)	20 (21.5)	6 (12.0)	19 (13.6)	21 (15.0)
Prior therapy for AMD — no. (%)					
Any	65 (45.5)	43 (46.2)	22 (44.0)	63 (45.0)	58 (41.4)
Extrafoveal or juxtafoveal laser photocoagulation	19 (13.3)	14 (15.1)	5 (10.0)	23 (16.4)	20 (14.3)
Medication†	1 (0.7)	1 (1.1)	0	1 (0.7)	1 (0.7)
Nutritional supplements	52 (36.4)	34 (36.6)	18 (36.0)	48 (34.3)	46 (32.9)
VA (letters) ^{‡§}					
Mean (SD)	45.5 (13.0)	46.4 (12.8)	43.9 (13.5)	47.0 (13.1)	47.1 (13.2)
<45 — no. (%)	66 (46.2)	42 (45.2)	24 (48.0)	63 (45.0)	60 (43.2)
≥45 — no. (%)	77 (53.8)	51 (54.8)	26 (52.0)	77 (55.0)	79 (56.8)
VA (approximate Snellen equivalent) ^{‡§} — no. (%)					
20/200 or worse	46 (32.2)	26 (28.0)	20 (40.0)	35 (25.0)	32 (23.0)
Better than 20/200 but worse than 20/40	97 (67.8)	67 (72.0)	30 (60.0)	103 (73.6)	101 (72.7)
20/40 or better	0	0	0	2 (1.4)	6 (4.3)
CNV lesion subtype — no. (%)					
Predominantly classic	141 (98.6)	91 (97.8)	50 (100)	134 (95.7)	135 (96.4)
Minimally classic	2 (1.4)	2 (2.2)	0	5 (3.6)	5 (3.6)
Occult with no classic	0	0	0	1 (0.7)	0
Total area of lesion (DA)					
Mean (SD)	1.88 (1.40)	1.85 (1.35)	1.93 (1.51)	1.89 (1.44)	1.79 (1.54)
Range	0.07–5.75	0.16–5.75	0.07–5.30	0.12–7.20	0.05–10.00
Total area of CNV					
Mean (SD)	1.48 (1.25)	1.47 (1.24)	1.50 (1.27)	1.48 (1.33)	1.31 (1.24)
Range	0.07–5.55	0.08–5.55	0.07–4.75	0.11–6.80	0.05–7.50
Area of classic CNV					
Mean (SD)	1.36 (1.13)	1.31 (1.06)	1.45 (1.25)	1.28 (1.05)	1.21 (1.12)
Range	0.07–5.55	0.08–5.55	0.07–4.75	0.00–6.40	0.05–5.30
Total area of leakage from CNV, + intense, progressive RPE staining (DA)					
Mean (SD)	3.06 (1.81)	3.07 (1.81)	3.04 (1.82)	3.00 (1.92)	2.92 (2.08)
Range	0.20–8.20	0.20–8.20	0.40–7.00	0.20–11.00	0.25–9.0

AMD = age-related macular degeneration; CNV = choroidal neovascularization; DA = disc areas; PDT = photodynamic therapy; RPE = retinal pigment epithelium; SD = standard deviation; VA = visual acuity.

*As reported by investigator on case report form.

†Medications used previously for treatment of AMD were the nonsteroidal anti-inflammatory drugs diclofenac sodium in the patient in the PDT group, diclofenac and flurbiprofen sodium in the patient in the 0.3-mg ranibizumab group, and ketorolac tromethamine in the patient in the 0.5-mg ranibizumab group.

‡Measured using Early Treatment Diabetic Retinopathy Study charts at a starting distance of 2 m.

§For ranibizumab 0.5-mg group, the number of patients with observations is 139.

Table 4. Frequency Distribution of Changes in Visual Acuity Relative to Baseline in the Study Eye at Month 24

Change in VA, n (%) [*]	Verteprorfin PDT (n = 143)	Ranibizumab 0.3 mg (n = 140)	Ranibizumab 0.5 mg (n = 140)
≥30 letters increase	3 (2.1)	12 (8.6)	20 (14.4)
25–29 letters increase	1 (0.7)	9 (6.4)	12 (8.6)
20–24 letters increase	2 (1.4)	6 (4.3)	12 (8.6)
15–19 letters increase	3 (2.1)	21 (15.0)	13 (9.4)
10–14 letters increase	7 (4.9)	20 (14.3)	17 (12.2)
5–9 letters increase	14 (9.8)	22 (15.7)	15 (10.8)
1–4 letters increase	8 (5.6)	10 (7.1)	16 (11.5)
No change	3 (2.1)	9 (6.4)	3 (2.2)
1–4 letters decrease	17 (11.9)	5 (3.6)	10 (7.2)
5–9 letters decrease	19 (13.3)	5 (3.6)	4 (2.9)
10–14 letters decrease	17 (11.9)	7 (5.0)	3 (2.2)
15–19 letters decrease	10 (7.0)	7 (5.0)	7 (5.0)
20–24 letters decrease	7 (4.9)	4 (2.9)	4 (2.9)
25–29 letters decrease	9 (6.3)	1 (0.7)	3 (2.2)
≥30 letters decrease	23 (16.1)	2 (1.4)	0

PDT = photodynamic therapy; VA = visual acuity.

^{*}For ranibizumab 0.5-mg group, the number of patients with observations is 139.

Table 6. Visual Acuity and Anatomical Characteristics in the Study Eye of Patients Randomized to Verteprorfin Photodynamic Therapy Who Did Not or Did Cross Over to Ranibizumab after Protocol Amendment^{*}

Characteristic/Evaluation Timepoint	Verteprorfin PDT/ No Crossover (n = 93)	Verteprorfin PDT/ Crossover (n = 50)
VA (letters)		
Baseline mean	46.4	43.9
Month 12 mean change	–12.5	–4.1
Month 18 mean change	–14.2	–5.4
Month 24 mean change	–12.1	–5.7
Total area of lesion (DA)		
Baseline mean	1.9	1.9
Month 12 mean change	+2.5	+2.6
Month 18 mean change	+2.7	+2.8
Month 24 mean change	+2.9	+2.9
Total area of CNV (DA)		
Baseline mean	1.5	1.5
Month 12 mean change	+1.4	+2.0
Month 18 mean change	+1.5	+1.9
Month 24 mean change	+1.6	+1.6
Area of classic CNV (DA)		
Baseline mean	1.3	1.5
Month 12 mean change	+0.5	+0.7
Month 18 mean change	+0.5	+0.5
Month 24 mean change	+0.5	+0.3
Total area of leakage from CNV + RPE staining [†] (DA)		
Baseline mean	3.1	3.0
Month 12 mean change	+0.4	+0.3
Month 18 mean change	–0.0	–0.7
Month 24 mean change	–0.2	–1.9
Patients with leakage from CNV + RPE staining [†] (%)		
Baseline %	100%	100%
Month 12 %	96%	88%
Month 18 %	89%	78%
Month 24 %	79%	40%

CNV = choroidal neovascularization; DA = disc areas; PDT = photodynamic therapy; RPE = retinal pigment epithelium; VA = visual acuity.

^{*}Earliest possible crossover was at month 18.

[†]Intense progressive RPE staining.

Table 8. Number (%) of Patients with Nonocular Hemorrhagic Event (Serious and Nonserious) during the 2-year ANCHOR Treatment Period

Nonocular Hemorrhagic Event	Verteporfin PDT (n = 143)	Ranibizumab	
		0.3 mg (n = 137)	0.5 mg (n = 140)
Total*	7 (4.9)	12 (8.8)	13 (9.3)
Epistaxis	4 (2.8)	2 (1.5)	2 (1.4)
Hematuria	1 (0.7)	2 (1.5)	2 (1.4)
Ecchymosis	0	0	4 (2.9)
Hematoma	0	2 (1.5)	2 (1.4)
Gastrointestinal hemorrhage	0	1 (0.7)	2 (1.4)
Postprocedural hemorrhage	2 (1.4)	0	0
Subdural hematoma	0	2 (1.5)	0
Upper gastrointestinal hemorrhage	0	2 (1.5)	0
Duodenal ulcer hemorrhage	0	0	1 (0.7)
Hemarthrosis	0	0	1 (0.7)
Hematemesis	0	1 (0.7)	0
Hematochezia	0	0	1 (0.7)
Hemothorax	0	1 (0.7)	0
Lower gastrointestinal hemorrhage	0	1 (0.7)	0
Mallory-Weiss syndrome	0	1 (0.7)	0
Peritoneal hemorrhage	0	1 (0.7)	0
Petechiae	1 (0.7)	0	0
Rectal hemorrhage	0	0	1 (0.7)
Small intestinal hemorrhage	0	1 (0.7)	0

ANCHOR = Anti-VEGF Antibody for the Treatment of Predominantly Classic Choroidal Neovascularization in Age-related Macular Degeneration; PDT = photodynamic therapy.

Note: Multiple occurrences of the same event in a patient were counted once in the overall incidence. The summary excludes adverse events that occurred after crossover to ranibizumab for patients in the verteporfin PDT group.

*Represents the number of subjects with at least 1 adverse event categorized as a nonocular hemorrhage.